

Effect of Separated Instruments on Apical Seal of Root Canals Obturated with Different Techniques: An In-vitro Stereomicroscopic Study

ASHWINI A NARAYANAN¹, JYOTI S MANDLIK², SARITA V SINGH³, ABHIJIT BAJIRAO JADHAV⁴,
RUCHIRA BHAMARE⁵, VINAYA PRABHANJAN INGALE⁶



ABSTRACT

Introduction: Practitioners often encounter challenges during root canal preparation, particularly with instrument separation. There is a need to understand how broken instruments interact with different obturation techniques.

Aim: To evaluate the extent of apical microleakage in root canals containing fractured instruments obturated using three different materials and techniques, and to investigate the interaction between fractured instruments and these obturation methods.

Materials and Methods: This in-vitro study was conducted at Bharati Vidyapeeth Deemed to be University Dental College and Hospital, Pune, Pune, Maharashtra, India, over a duration of three months, from February 2024 to April 2024. Total 45 single-rooted premolars were decoronated and prepared with hand and rotary files upto size 20. A #25 rotary file was scratched and fractured 3 mm from the tip at the apex. Samples were randomly assigned to three obturation groups (n=15 each): Group A {Mineral Trioxide Aggregate (MTA)}, Group B (lateral compaction), and Group C (injectable gutta-percha). Roots were coated with nail varnish, sparing the apical 2 mm. The parameters studied included the degree of apical microleakage, which was measured by sectioning samples after 48 hours of immersion in methylene blue dye for observation under a stereomicroscope.

Statistical analysis was performed using Statistical Package of Social Sciences (SPSS) version (IBM Corp, v.21.0). Intergroup comparison of apical microleakage (in mm) between different groups was conducted using One-way Analysis of Variance (ANOVA). Level of significance was set at $p < 0.05$.

Results: Intergroup comparison of apical microleakage (in mm) between different groups was performed using One-way ANOVA. This comparison showed statistically significant differences (p -value=0.047*) between the three groups. Pair-wise multiple Post-hoc comparison of apical microleakage (in mm) between different groups was performed using Tukey's Post-hoc test. Group A (MTA) exhibited significantly lower microleakage (1.59 mm) compared to Group B (lateral compaction, 1.83 mm) and Group C (injectable gutta-percha, 2.25 mm). Groups A and B showed p -value of 0.047*, and Groups A and C showed p -value of 0.027*. No significant differences were found between Groups B and C (p =0.558).

Conclusion: The MTA obturation demonstrated superior sealing capability compared to the other techniques, while comparable leakage was observed in the lateral compaction and injectable gutta-percha groups. These findings highlight the effectiveness of MTA in managing apical microleakage in the presence of fractured instruments.

Keywords: Dental instruments, Endodontics, Gutta-percha, Root canal filling materials

INTRODUCTION

Root canal instrumentation and preparation wield significant influence over the success of further procedures in endodontic therapy [1]. The dynamic motion of instruments, coupled with the spaces generated during and post-instrumentation, serve as a facilitator for the infiltration and flow of irrigants throughout the canal system, contributing to comprehensive canal debridement. The resultant canal shape, meticulously crafted by the instruments, plays a crucial role in achieving a secure seal of the root canal system [2]. Negotiation and establishment of the glide path constitute the initial and vital phases of chemo-mechanical procedures, serving as indispensable steps for thoroughly evaluating the intricate anatomy of root canals and ensuring unimpeded access to the apical region. These critical processes become notably challenging in the context of curved and narrow canals, potentially introducing procedural complexities or errors [3,4], such as damage to the apical foramen, file separation, strip perforation, elbows, zips, perforation, ledging, and apical blockage [5]. The one of the most challenging errors is separation of endodontic instruments within the root canal. Previous literature reports an incidence rate of separated instruments ranging from 0.5 to 5% in investigated cases. The presence of retained

Separated Endodontic Files (SEF) can significantly influence treatment outcomes and impede both mechanical and chemical aspects of root canal treatment [6]. Broken instruments pose challenges to achieving comprehensive cleaning and shaping, potentially compromising treatment success. Fracture rates for rotary Nickel Titanium (NiTi) files range from 0.4 to 5%, indicating a greater risk in contrast to stainless steel files [7].

The obturation phase in the non surgical endodontic treatment holds paramount importance, emphasising the necessity of achieving a hermetic seal to obstruct the re-entry of microorganisms. A persistent challenge in endodontics is treatment failure, frequently attributed to the absence of a sound apical seal, underscoring the critical role this factor plays in ensuring the overall success of endodontic interventions [8].

Instrument fragments within the root canal can have negative consequences hindering effective preparation and cleaning of the root canal, thus potentially affecting the prognosis [9]. Despite efforts to minimise it, NiTi instrument separation remains an unpredictable concern [10,11]. Retrieving broken instruments from the root canal proves highly difficult and often yields limited success in many cases [12]. Currently, there is no established protocol for safely and

effectively removing instruments broken in the canal, as efforts to do so may result in excessive dentin cutting, ledging, perforation, difficulties with thin and curved roots, and potential extrusion of fragments through the anatomic foramen [13-16].

To address these challenges, some authors have proposed that the broken instrument can be left in the canal, with the canal coronal to the instrument being obturated using standard procedures [17,18]. In response to growing apprehensions surrounding the management of broken instruments within root canals, this research attempts to delve into the intricacies by undertaking a comprehensive comparison of apical microleakage. Previous studies on apical microleakage in root canals with fractured instruments have predominantly focused on a single obturation technique [19,20]. While this provides useful insights, it may not comprehensively reflect the range of obturation methods commonly employed in clinical practice. In real-world scenarios, clinicians often choose from a variety of techniques, such as lateral condensation, warm vertical compaction, or thermoplasticised techniques, based on the specific case and anatomical challenges. As such, limiting the investigation to just one obturation technique may overlook potential variations in microleakage outcomes that could arise from the diversity of techniques used in routine endodontic procedures.

Another study evaluated apical microleakage in root canals with different rotary file systems; however, the study did not incorporate obturated samples and primarily examined the effect of the file systems on leakage without addressing the potential influence of different obturation techniques [21]. Therefore, the present study aimed to address these gaps by evaluating three obturation methods to provide a more comprehensive understanding of microleakage in such cases.

MATERIALS AND METHODS

This original in-vitro study was conducted at Bharati Vidyapeeth Deemed to be University Dental College and Hospital, Pune, India, over a duration of three months. Departmental clearance was obtained from the Institutional Research Committee (IRC) (Approval No. BVDUDCH/2022-23/414 A), and ethical approval was granted by the Institutional Ethics Committee (IEC) (Approval No. BVDU/IEC/R2/08/22-23). Total 45 single-rooted, single-canaled premolars, extracted for orthodontic purposes, were used for the study.

Sample size calculation: The sample size calculation provided has been calculated by "comparing two means" formula using Epi Info software (v.3.0).

$$n = \frac{(\sigma_1^2 \sigma_2^2 / \kappa) (Z_{1-\alpha/2} + Z_{1-\beta})^2}{\Delta^2}$$

Where, σ_1 =standard deviation of Group-1,

σ_2 =standard deviation of Group-2

Δ =difference in group means [8].

The Mean \pm SD, variance for Group 1 and Group 2 were 3.94 \pm 0.81, 5.15 \pm 1.27, 0.6561, 1.6129, respectively. The difference was -1.21.

κ =ratio= $n_2/n_1=1$

$Z_{1-\alpha/2}$ =two-sided Z value (eg. Z=1.96 for 95% confidence interval).

$Z_{1-\beta}$ =power of the study (80% power, critical value of 0.84)

Substituting the values in the above formula:

$n=15$ samples per group

A minimum sample size of 15 samples per group is derived. Considering three groups, the total sample size of 45 samples is derived.

Total sample size=45 samples

Study Procedure

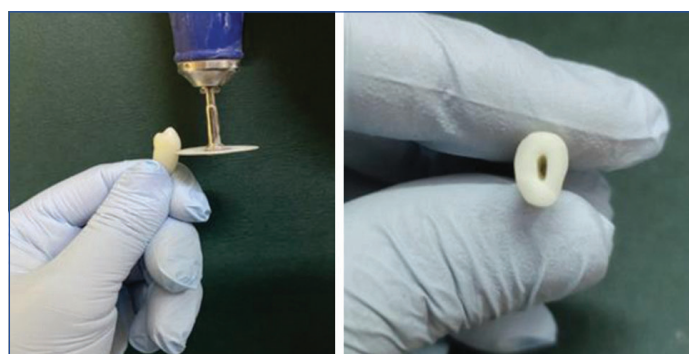
Freshly extracted, non carious single-rooted teeth with comparable root canal morphology and completely formed roots were included, excluding those with restorations, root resorption, previous root canal

therapy, bifurcated or calcified canals, and any defects or fractures. Immediately after extraction, the teeth underwent cleaning and disinfection with 5.25% sodium hypochlorite solution. Subsequently, the teeth were stored in a 0.9% saline solution at room temperature till the commencement of the experiment [Table/Fig-1].

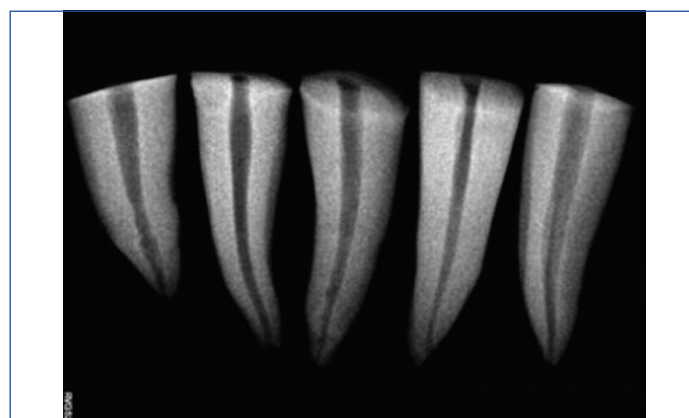


[Table/Fig-1]: Total 45 extracted single-rooted premolars collected for the study.

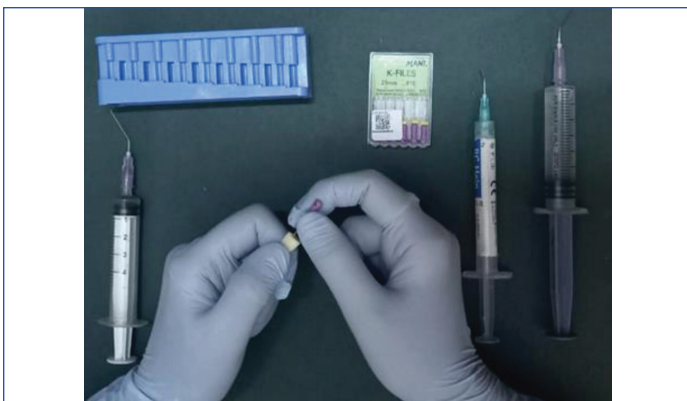The teeth were decoronated with a diamond disc in a micromotor straight handpiece utilising water coolant as an irrigant [Table/Fig-2a,b]. A preoperative radiograph was taken in the mesiodistal direction to establish the working length [Table/Fig-3]. The canals were subsequently prepared using hand K-files (Dentsply Maillefer, Ballaigues, Switzerland), followed by rotary files (Neoendo VDW, Munich, Germany). Recapitulation was done between file usage, and the canals were flushed with a solution of 5.25% sodium hypochlorite. Final irrigation was performed using 17% Ethylenediamine Tetracetic Acid (EDTA), and then 5 mL of physiologic saline [Table/Fig-4]. An intentional scratch was made on a #25 rotary file, positioned 3 mm from its tip, using a high-speed handpiece, and it was deliberately fractured at the root apex. Radiographs were taken after the file was fractured to ensure the location of file till apical foramen [Table/Fig-5].



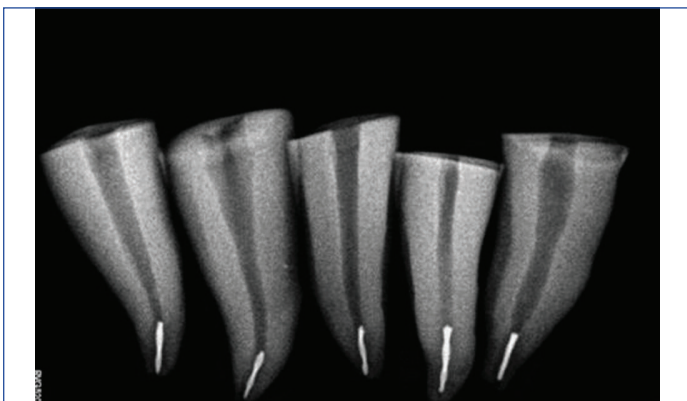
[Table/Fig-2]: Decoronation of the tooth: (a) Decoronation of the tooth using a diamond disc and micromotor handpiece; (b) Occlusal view post-decoronation showing the cervical surface.



[Table/Fig-3]: Preoperative radiograph (mesiodistal view) taken to establish the working length.



[Table/Fig-4]: Chemo-mechanical preparation.



[Table/Fig-5]: File fractured at apical third.

These samples were equally assigned to three different groups (n=15) for subsequent filling with the experimental filling material/technique as follows:

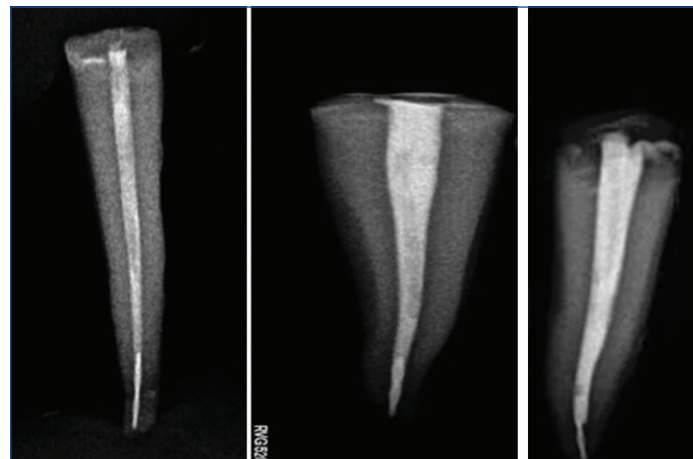
- Group A: Samples obturated using MTA.
- Group B: Samples obturated using the lateral compaction technique.
- Group C: Samples obturated using injectable gutta-percha.

Obturation techniques:

- Group A: The canals were dried, and MTA (Angelus, Londrina, Brazil/Clinician's Choice, New Milford, CT) was mixed according to the manufacturer's guidelines. Using a mesial gun, it was packed into the canals, and radiographs were taken [Table/Fig-6].
- Group B: The samples were obturated using lateral compaction technique. The master gutta-percha cone (Dentsply Maillefer, Tulsa, Oklahoma, USA) was selected, canals were dried, and AH Plus root canal sealer (Dentsply Maillefer, Tulsa, Oklahoma, USA) was applied using No. 15 K file. The master cone, coated with AH Plus sealer, was then inserted into the canal till the working length. A spreader was used to create space for accessory cones. Non standardised accessory gutta-percha cones were used to completely fill the canal space. The excess gutta-percha was seared off at the orifice, and radiographs were taken [Table/Fig-7].
- Group C: The samples were obturated using thermoplasticised gutta-percha (Fi-G, Woodpecker). The canals were dried, and the tip size for the gutta-percha injection was selected according to the canal size (tip size 40/0.025). The device was heated up to 180°C, the plasticised gutta-percha was injected forcefully into the canal, and it was immediately compacted to facilitate its flow till the apical area. Post-obturation radiographs were taken [Table/Fig-8].

Microleakage was assessed using the dye penetration technique. Nail varnish was applied to the roots up to 2 mm around the apex [Table/Fig-9], and glass ionomer cement (GC, Gold Label, GC Corp., Tokyo, Japan) was used to seal the coronal opening. The roots were

submerged in methylene blue dye [Table/Fig-10] for a duration of 48 hours. After rinsing, mesiodistal sectioning of the roots was done using a cutting saw [Table/Fig-11].



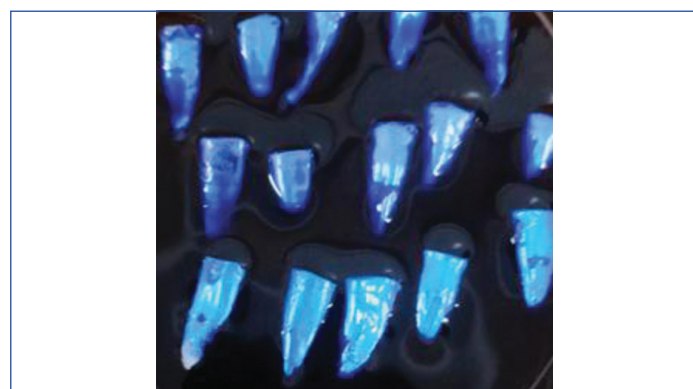[Table/Fig-6]: Group A: Samples with files separated at their apical third and obturated using MTA.

[Table/Fig-7]: Group B: Samples with files separated at their apical third and obturated using gutta-percha, lateral compaction technique.

[Table/Fig-8]: Group C: Samples with files separated at their apical third and obturated using injectable gutta-percha technique (Warm vertical compaction). (Images from left to right)



[Table/Fig-9]: Samples coated with nail varnish except 2 mm around the root apex.

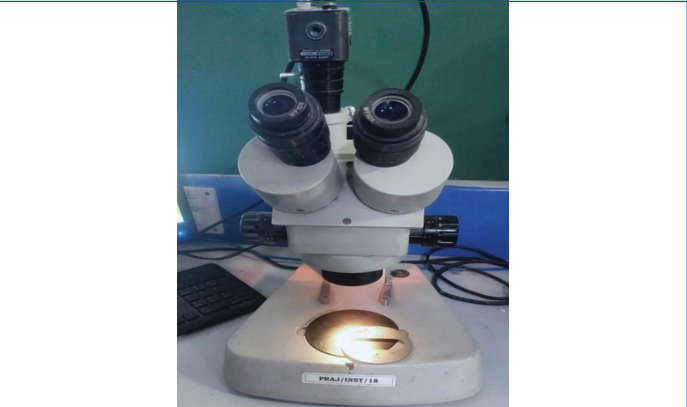


[Table/Fig-10]: Immersion in methylene blue dye.



[Table/Fig-11]: Sectioned specimen ready for viewing through the stereomicroscope.

A stereo microscope (Wuzhou New Found Instrument Co. Ltd., China, Model: XTL 3400E, Magnification: 10X) [Table/Fig-12] was used to observe the segments, and the dye penetration depth was measured using an Image Analysis System (Chroma Systems Pvt., Ltd., India, Model: MV IG 2005).



[Table/Fig-12]: Image showing a stereomicroscope (Wuzhou New Found Instrument Co. Ltd., China, Model: XTL 3400E) with a magnification of 10X.

STATISTICAL ANALYSIS

The data was entered and organised using Microsoft Excel (v.2013), and statistical analyses were conducted with SPSS software (IBM Corp, version 21.0). Both descriptive and inferential statistics were performed for the parameters studied. Post-hoc multiple comparison was conducted using Tukey's Post-hoc test to evaluate significant group differences. In this study, statistical significance was determined using a 95% confidence interval, with a p-value threshold of less than 0.05.

RESULTS

The descriptive statistics of apical microleakage (in mm) across the different groups, along with the inter group comparisons of apical microleakage has been depicted in [Table/Fig-13].

Groups	Group-A: MTA	Group-B: Lateral compaction technique	Group-C: Injectable gutta-percha
N	15	15	15
Range	0.00-2.92	0.62-2.99	0.00-4.30
Mean	1.59	1.83	2.25
Standard deviation	0.79	0.69	1.61
ANOVA comparison	Sum of squares=3.364		
	df=2		
	Mean square=1.682		
	F=1.353		
	p-value=0.047*		

[Table/Fig-13]: Descriptive statistics and intergroup comparison of apical microleakage (in mm) amongst different groups
*p-value <0.05 statistically significant


Interpretation: In the present study, apical microleakage showed statistically significant differences (p-value=0.047) between the three groups [Table/Fig-13]. This comparison showed statistically significant differences (p-value <0.05) between Groups A and B, as well as between Groups A and C. Thus, it can be concluded that apical microleakage is minimal in Group A (MTA) and statistically significant compared to Groups B and C.

The pairwise multiple Post-hoc comparison of apical microleakage (in mm) between the different groups has been depicted in [Table/Fig-14]. The mean microleakage in Group A (MTA obturation) was observed to be 1.59 mm, which was the lowest value in our study compared to all other groups. Group A (MTA, 1.59 mm) showed lower microleakage than Group B (Lateral compaction technique, 1.83 mm) and Group C (Injectable gutta-percha, 2.25 mm). Pairwise

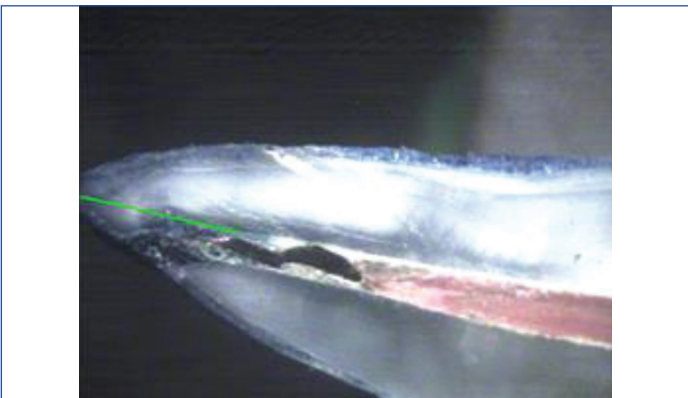
multiple Post-hoc comparison of apical microleakage (in mm) between different groups was performed using Tukey's Post-hoc test. This comparison revealed statistically significant differences (p-value <0.05) between Groups A and B, and Groups A and C. Stereomicroscopic images of all groups has been depicted in [Table/Fig-15-17]. Thus, it can be concluded that apical microleakage is minimal with Group A (MTA) and statistically significant compared to Groups B and C.

	(I) Comparison groups	(J) Groups	Mean difference (I-J)	p-value
Apical microleakage (in mm)	Group-A : MTA	Group-B: Lateral compaction technique	-.23933	.047*
		Group-C: Injectable gutta-percha	-.66133	.027*
	Group-B: Lateral compaction technique	Group-A: MTA	.23933	.047*
		Group-C: Injectable gutta-percha	-.42200	.558
	Group-C: Injectable gutta-percha	Group-A: MTA	.66133	.027*
		Group-B: Lateral compaction technique	.42200	.558

[Table/Fig-14]: Pairwise multiple Post-hoc comparison of apical microleakage (in mm) between different groups.
*p-value <0.05 statistically significant



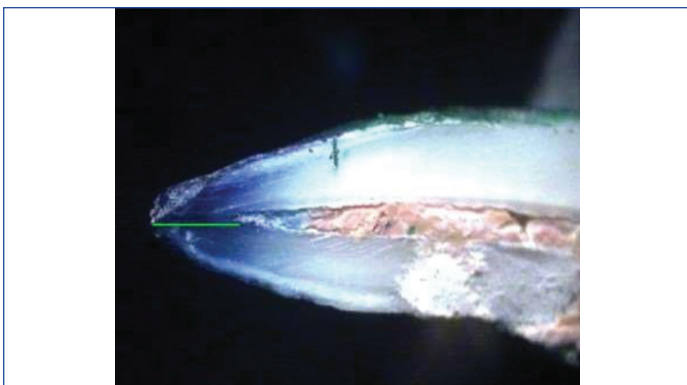
[Table/Fig-15]: Stereomicroscopic image of Group-A (MTA group) showing minimal dye penetration, indicating lower apical microleakage. The green line in the image represents the linear measurement of dye penetration. This system provides real-time measurements on the screen, ensuring precision. The image illustrates the specific region of interest and the methodology used to obtain the data.



[Table/Fig-16]: Stereomicroscopic image of Group-B (Lateral compaction group) showing moderate dye penetration, suggesting higher apical microleakage compared to Group-A.

DISCUSSION

The present study investigated the apical microleakage of teeth with the fractured instrument in the apical region, which were obturated with three distinct techniques using a stereomicroscope. NiTi rotary instruments were deliberately fractured at the apical third for experimental purposes. A stereomicroscope was employed to



[Table/Fig-17]: Stereomicroscopic image of Group-C (Injectable gutta-percha group) displays the highest degree of dye penetration, indicating the greatest apical microleakage among the three groups.

evaluate the maximum depth of dye penetration along the gutta-percha. The conventional measurement method involves determining the point of coronal penetration to the constriction at the apex [22]. But in present study, a computer and digital camera with suitable software were used to measure the linear depth of dye penetration in micrometers. The data displayed in the image was obtained using calibrated software integrated with the stereomicroscope laboratory imaging system. Although the numerical display of the measurements is not visible in the static images, they were carefully documented and used for further analysis in present study.

As per the findings of this investigation, all experimental groups exhibited apical microleakage, with the least microleakage in Group A (MTA obturation, mean value 1.59 mm). Conversely, the highest degree of microleakage was observed in Group C (Injectable gutta-percha, mean value 2.25 mm).

Godiny M et al., conducted a comparison of apical microleakage in root canals containing fractured instruments. The canals were filled using MTA and CEM cement, as well as gutta-percha with both lateral compaction and injection techniques. They utilised dye penetration techniques and reported superior results with MTA and CEM cement. The present results are in alignment with these findings [8]. In the present study, samples in Group B (lateral compaction obturation, mean value 1.83 mm) exhibited reduced microleakage than Group C, but the microleakage was more than that of Group A. The introduction of additional accessory cones for lateral compaction might have contributed to this reduction in leakage.

In Group C, samples were filled with thermoplasticised gutta-percha. The method involves an injection syringe, cannulas equipped with a 22 G needle, and a portable 120 V heater preset at 90°C, with the temperature adjustable up to 180°C. The injection syringe, along with the attached cannula, was heated for 15 minutes, facilitating the flow of gutta-percha at approximately 70°C. In a study by Keshava Prasad BS, Nageswar Rao R it was found that the mean leakage of injectable gutta-percha was less in comparison to thermo-compacted and laterally compacted gutta-percha; but the difference between the groups was not found to be statistically significant [23]. No statistical difference in leakage was found between lateral compaction and injectable gutta-percha in studies conducted by ElDeeb ME and Greene HA et al., [24,25].

In the present study, samples obturated with thermoplasticised gutta-percha using Fi-G (Woodpecker) exhibited the highest levels of microleakage. This contradicts earlier research that suggested injectable gutta-percha obturation resulted in significantly less leakage compared to cold lateral compaction [21-25]. This discrepancy may be attributed to contraction of thermoplasticised gutta-percha after cooling, creating space for dye leakage within the canal. Additionally, in our study, in Group-B, sealer used might have flown in the gaps between canal wall and the broken instrument, achieving seal to some extent whereas the thermoplasticised gutta-

percha in Group C might not have reached the apical level owing to its less flow compared to sealer. Moreover, the broken instrument might have negated the flow of gutta-percha apically.

It's worth noting that in the present study, injectable gutta-percha exhibited higher microleakage values, suggesting that alternative obturation methods might be more effective in achieving thorough and reliable obturations, potentially reducing failure rates. It's important to be prudent when correlating the findings of present study to practical scenarios, as the quality of sealing following instrument fracture is just one of many factors that can impact a patient's response to treatment. Research suggests that preoperative periapical radiolucency may have a greater clinical significance than the presence of a fractured NiTi instrument in predicting treatment success. Therefore, while addressing issues related to fractured instruments is essential, clinicians should also consider other factors, such as preoperative conditions, when determining the prognosis of endodontic procedures.

Limitation(s)

The present study has a few limitations that should be considered when interpreting the results. The sample size of 45 premolars, while sufficient for detecting significant differences, may limit the generalisability of the findings, and a larger sample size could enhance the robustness of the results. Additionally, the study's in-vitro nature, conducted under controlled laboratory conditions, does not fully replicate the complexity of the clinical environment, potentially impacting external validity. The use of single-rooted premolars exclusively may limit the applicability of these results to other tooth types with more complex root canal anatomies. Finally, the 48-hour dye immersion period used to measure apical microleakage, although standard in similar research, may not reflect long-term leakage behaviour in actual clinical scenarios.

CONCLUSION(S)

In conclusion, the present study findings indicate significant variation in apical microleakage among different obturation techniques. While MTA obturation demonstrates superior sealing capacity, lateral compaction and injectable gutta-percha techniques may be associated with varying degrees of microleakage. These insights emphasise the importance of selecting an appropriate obturation technique based on its sealing efficacy to enhance the success of endodontic treatment. Regarding MTA's sealing capacity compared to lateral condensation and thermoplasticised techniques, MTA demonstrates markedly superior sealing capacity. This highlights the effectiveness of MTA in filling root canals, especially those containing fractured instruments. However, further comprehensive in-vivo investigations are essential to fully validate and extend these findings to clinical practice. Such studies will provide valuable insights into the real-world applicability and performance of MTA in endodontic treatment in cases with iatrogenic errors like instrument separation.

REFERENCES

- [1] Yared G. Canal preparation using only one Ni-Ti rotary instrument: Preliminary observations. *Int Endod J.* 2008;41(4):339-44.
- [2] Paqué F, Balmer M, Attin T, Peters OA. Preparation of oval-shaped root canals in mandibular molars using nickel-titanium rotary instruments: A micro-computed tomography study. *J Endod.* 2010;36(4):703-07.
- [3] Ajuz NCC, Armada L, Gonçalves LS, Debelian G, Siqueira JF. Glide path preparation in S-shaped canals with rotary pathfinding nickel-titanium instruments. *J Endod.* 2013;39(4):534-37.
- [4] Pettiette MT, Metzger Z, Phillips C, Trope M. Endodontic complications of root canal therapy performed by dental students with stainless-steel Kfiles and Nickel-titanium hand files. *J Endod.* 1999;25(4):230-34.
- [5] Hülsmann M, Peters OA, Dummer PMH. Mechanical preparation of root canals: Shaping goals, techniques and means. *Endod Top.* 2005;10(1):30-76.
- [6] Pedir SS, Mahran AH, Beshir K, Baroudi K. Evaluation of the factors and treatment options of separated endodontic files among dentists and undergraduate students in Riyadh area. *J Clin Diagn Res.* 2016;10(3):ZC18-23.
- [7] Alapati SB, Brantley WA, Svec TA, Powers JM, Nusstein JM, Daehn GS. SEM observations of Nickel-Titanium rotary endodontic instruments that Fractured During Clinical Use. *J Endod.* 2005;31(1):40-43.

- [8] Godiny M, Hatam R, Khavid A, Khanlari S. Apical microleakage in root canals containing broken rotary instruments. *Iran Endod J.* 2017;12(3):360-65.
- [9] Lin LM, Rosenberg PA, Lin J. Do procedural errors cause endodontic treatment failure? *J Am Dent Assoc.* 2005;136:187-93; quiz 231.
- [10] Parashos P, Messer HH. Rotary NiTi Instrument fracture and its consequences. *J Endod.* 2006;32(11):1031-43.
- [11] Hulsman M, Schinkel I. Influence of several factors on the success or failure of removal of fractured instruments from the root canal. *Endod Dent Traumatol.* 1999;15:252-58.
- [12] Hulsman M. Removal of silver cones and fractured instruments using the canal finder system. *J Endod.* 1990;16:596-600.
- [13] Hulsman M. Methods for removing metal obstructions from the root canal. *Endod Dent Traumatol.* 1993;9:223-37.
- [14] Gaffney JL, Lehman JW, Miles MJ. Expanded use of the ultrasonic scaler. *J Endod.* 1981;7:228-29.
- [15] Nagai O, Tani N, Kayaba Y, Kodama S, Osada T. Ultrasonic removal of broken instruments in root canals. *Int Endod J.* 1986;19:298-304.
- [16] Fors UG, Berg JO. Endodontic treatment of root canals obstructed by foreign objects. *Int Endod J.* 1986;19:02-10.
- [17] Crump MC, Natkin E. Relationship of broken root canal instruments to endodontic case prognosis: A clinical investigation. *J Am Dent Assoc.* 1970;80(6):1341-47.
- [18] Fox J, Moodnik RM, Greenfield E, Atkinson JS. Filling root canals with files: Radiographic evaluation of 304 cases. *N Y State Dent J.* 1972;38:154-57.
- [19] Saunders JL, Eleazer PD, Zhang P, Michalek S. Effect of a separated instrument on bacterial penetration of obturated root canals. *J Endod.* 2004;30(3):177-79.
- [20] Sandhu RM, Bhullar KK, Handa A, Sran SS. Comparative evaluation of apical microleakage in root canals containing separated endodontic files- An in-vitro study. *J Pharma Res Int.* 2024;36(7):156-63.
- [21] Hasheminia SM, Farhad A, Davoudi H, Sarfaraz D. Microleakage of five separated nickel titanium rotary file systems in the apical portion of the root canal. *Dent Res J (Isfahan).* 2022;6(1):19:46.
- [22] Saeidi A, Hajipour R, Mahmoudi E, Feizi F, Khafri S. Comparison of the apical seal obtained by Adseal, Proseal, and AH26 sealers in root canal obturation with lateral compaction technique. *Dent Res J (Isfahan).* 2023;20:94.
- [23] Keshava Prasad BS, Nageswar Rao R. Comparative sealing ability of injectable thermoplasticised gutta percha, thermocompaction and lateral condensation: An in-vitro study. *Ann Dent Spec.* 2015;3(1):01-05.
- [24] Eldeeb ME. The sealing ability of injection-molded thermoplasticized gutta percha. *J Endod.* 1985;11(2):84-86.
- [25] Greene HA, Wong M, Ingram TA 3rd. Comparison of the sealing ability of four obturation techniques. *J Endod.* 1990;16(9):423-28.

PARTICULARS OF CONTRIBUTORS:

1. Postgraduate Student, Department of Conservative Dentistry and Endodontics, Bharati Vidyapeeth (Deemed to be University), Dental College and Hospital, Pune, Maharashtra, India.
2. Professor, Department of Conservative Dentistry and Endodontics, Bharati Vidyapeeth (Deemed to be University), Dental College and Hospital, Pune, Maharashtra, India.
3. Associate Professor, Department of Conservative Dentistry and Endodontics, Bharati Vidyapeeth (Deemed to be University), Dental College and Hospital, Pune, Maharashtra, India.
4. Assistant Professor, Department of Conservative Dentistry and Endodontics, Bharati Vidyapeeth (Deemed to be University), Dental College and Hospital, Pune, Maharashtra, India.
5. Assistant Professor, Department of Conservative Dentistry and Endodontics, Bharati Vidyapeeth (Deemed to be University), Dental College and Hospital, Pune, Maharashtra, India.
6. Assistant Professor, Department of Conservative Dentistry and Endodontics, Bharati Vidyapeeth (Deemed to be University), Dental College and Hospital, Pune, Maharashtra, India.

NAME, ADDRESS, E-MAIL ID OF THE CORRESPONDING AUTHOR:

Dr. Jyoti S Mandlik,
Professor, Department of Conservative Dentistry and Endodontics, Bharati Vidyapeeth (Deemed to be University), Dental College and Hospital, Pune-411043, Maharashtra, India.
E-mail: jyoti.mandlik@bharativedyapeeth.edu

PLAGIARISM CHECKING METHODS: [Jain H et al.]

- Plagiarism X-checker: Jul 24, 2024
- Manual Googling: Dec 04, 2024
- iThenticate Software: Dec 12, 2024 (10%)

ETYMOLOGY: Author Origin**EMENDATIONS:** 7**AUTHOR DECLARATION:**

- Financial or Other Competing Interests: None
- Was Ethics Committee Approval obtained for this study? Yes
- Was informed consent obtained from the subjects involved in the study? No
- For any images presented appropriate consent has been obtained from the subjects. No

Date of Submission: Jul 23, 2024

Date of Peer Review: Oct 27, 2024

Date of Acceptance: Dec 14, 2024

Date of Publishing: Apr 01, 2025